



# Comparison of safety, efficacy, and patient satisfaction with thermal ablation versus endoscopic thyroidectomy for benign thyroid nodules in a propensity-matched cohort

Ting-Chun Kuo, MD, PhD<sup>a,b</sup>, Kuen-Yuan Chen, MD, PhD<sup>a</sup>, Chieh-Wen Lai, MD, PhD<sup>d</sup>, Yi-Chia Wang, MD<sup>c</sup>, Ming-Tsan Lin, MD, PhD<sup>a</sup>, Chin-Hao Chang, PhD<sup>e</sup>, Ming-Hsun Wu, MD, PhD<sup>a,\*</sup>

**Background:** Thyroid nodules (TNs) often require intervention due to symptomatic or cosmetic concerns. Radiofrequency ablation (RFA) has shown promise as a treatment option, offering potential advantages without neck scars. Recently, the scarless treatment alternative of transoral endoscopic thyroidectomy vestibular approach (TOETVA) has emerged. When surgery can be performed in a scarless manner, it remains unclear whether ablation is still the preferred treatment choice. This study aims to compare the safety, efficacy, and patient satisfaction of RFA and TOETVA.

**Study design:** A retrospective data analysis was conducted on patients treated with RFA or TOETVA for unilateral benign TNs between December 2016 and September 2021. Propensity score matching was employed to create comparable groups. Various clinicopathologic parameters, treatment outcomes, and costs were assessed.

**Results:** Of the 2814 nonfunctional thyroid nodules treated during this period, 642 were benign and unilateral. A total of 121 and 100 patients underwent thermal ablation and transoral endoscopic thyroidectomy, respectively. After matching, 84 patients were selected for each group. Both RFA and TOETVA demonstrated low complication rates, with unique complications associated with each procedure. Treatment time ( $30.8 \pm 13.6$  vs.  $120.7 \pm 36.5$  min,  $P < 0.0001$ ) was shorter in the RFA group. Patient satisfaction (significant improvement: 89.3% vs. 61.9%,  $P < 0.0001$ ) and cosmetic results (cosmetic score 1–2: 100.0% vs. 54.76%,  $P < 0.0001$ ) favored TOETVA. RFA was found to be less costly for a single treatment, but the cost of retreatment should be considered. The histological diagnoses post-TOETVA revealed malignancies in 9 out of 84 cases, underscoring the significance of follow-up assessments.

**Conclusion:** Scarless procedures, RFA and TOETVA, are effective for treating unilateral benign TNs, each with unique advantages and drawbacks. While RFA is cheaper for a single treatment, TOETVA offers superior cosmetic results and patient satisfaction. Further research is needed to evaluate long-term safety and cost-effectiveness. It is crucial to remain vigilant about the possibility of malignancy despite benign cytology pre-treatment.

**Keywords:** Benign thyroid nodule, minimally invasive procedure, radiofrequency ablation (RFA), scarless procedures, thyroidectomy, transoral endoscopic thyroidectomy vestibular approach (TOETVA)

## Introduction

While most thyroid nodules (TNs) are benign and require only serial observation, some may necessitate treatment for symptomatic or cosmetic reasons<sup>[1,2]</sup>. Thyroidectomy is considered the

golden surgical approach for TNs; however, surgery carries risks and can lead to neck scarring, which may concern patients<sup>[3]</sup>.

Thermal ablation has shown promise in treating benign TNs<sup>[4–6]</sup>. Previous studies have compared radiofrequency ablation (RFA) with conventional transcervical open thyroidectomies<sup>[7]</sup> and

Departments of <sup>a</sup>Surgery, <sup>b</sup>Traumatology, <sup>c</sup>Anesthesiology, National Taiwan University Hospital, <sup>d</sup>Department of Surgery, Buddhist Tzu Chi General Hospital and <sup>e</sup>Department of Medical Research, National Taiwan University Hospital & National Taiwan University, Taipei, Taiwan

Sponsorships or competing interests that may be relevant to content are disclosed at the end of this article.

\*Corresponding author. Address: Department of Surgery, National Taiwan University Hospital, No. 7, Chung Shan S. Rd., Taipei 10002, Taiwan. Tel.: +886 223 123 456; fax: +886 223 222 890. E-mail: dtsurgp9@gmail.com (M-H. Wu).

Copyright © 2024 The Author(s). Published by Wolters Kluwer Health, Inc. This is an open access article distributed under the terms of the Creative Commons Attribution-Non Commercial License 4.0 (CCBY-NC), where it is permissible to download, share, remix, transform, and buildup the work provided it is properly cited. The work cannot be used commercially without permission from the journal.

International Journal of Surgery (2024) 110:2568–2576

Received 23 November 2023; Accepted 4 February 2024

Supplemental Digital Content is available for this article. Direct URL citations are provided in the HTML and PDF versions of this article on the journal's website, [www.com/international-journal-of-surgery](http://www.com/international-journal-of-surgery).

Published online 19 February 2024

<http://dx.doi.org/10.1097/JS9.0000000000001201>

have concluded that ablation is as effective as surgery but may have potential advantages in safety and cosmetic effects without neck scars, one of the most important factors affecting patients' quality of life<sup>[8]</sup>. Additionally, ablation preserves thyroid function and is, therefore, more suitable than surgery for bilateral benign TNs. The transoral endoscopic thyroidectomy vestibular approach (TOETVA) is an innovative, scarless method that takes into account cosmetic considerations for the patient and has demonstrated low surgical morbidity as the technology matures<sup>[9,10]</sup>. Thyroxine replacement therapy is seldom required after hemithyroidectomy<sup>[11]</sup>. RFA is emerging as a promising treatment option, in the context of surgery conducted without scarring, determining the preferable treatment choice between ablation and scarless surgery remains uncertain. This study is designed to systematically compare the safety, efficacy, and patient satisfaction of RFA and TOETVA in demographically matched cohorts with unilateral benign thyroid nodules.

## Materials and methods

### Patient eligibility and study design

We conducted a retrospective review of all patients with TNs who underwent invasive treatments, including thyroidectomies and thermal ablations, between December 2016 and September 2021 at a university hospital. Exclusion criteria encompassed (1) age below 20 years, (2) hyperfunctioning nodules associated with ongoing thyrotoxicosis, (3) preoperative cytological diagnoses other than benign nodules, (4) treatment for bilateral nodules or retrosternal goitres, and (5) procedures other than TOETVA or RFA. This study received approval from the Research Ethics Committee of our institution and was registered on ClinicalTrials.gov.

Out of the 2814 TN cases treated during this period, 642 were identified as benign and unilateral. This study included patients who underwent minimally invasive procedures such as TOETVA ( $n = 100$ ) or RFA ( $n = 121$ ) (Fig. 1).

The indications for RFA or TOETVA at our institution included TN-related cosmetic or compressive symptoms and the cytologically confirmed benign nature of the nodules that continued to grow. Patients provided their consent and chose the minimally invasive procedure after comprehensive discussions with the surgeons regarding the indications. Typically, in our institution's protocol, TNs with a largest diameter greater than 8 cm were not considered for RFA or TOETVA.

All patients underwent preoperative evaluation through sonography, and fine-needle aspiration cytology was performed at least twice<sup>[12]</sup>. All surgeons who performed these procedures had more than 6 years of experience in TOETVA or RFA. After TOETVA, histopathological data were reviewed by at least two experienced pathologists. The work has been reported in line with the STROCSS criteria, Supplemental Digital Content 2, <http://links.lww.com/JIS9/B950><sup>[13]</sup>.

### Transoral endoscopic thyroidectomy

The surgical procedure for TOETVA followed the protocol proposed by Anuwong<sup>[2]</sup>, and intraoperative neuromonitoring was conducted in all cases in accordance with the guidelines of the International Neuromonitoring Study Group<sup>[14]</sup>. Intraoperative signal loss and the mechanisms of recurrent laryngeal nerve

## HIGHLIGHTS

- Both radiofrequency ablation (RFA) and transoral endoscopic thyroidectomy vestibular approach (TOETVA) are effective scarless procedures for treating benign thyroid nodules, each having its unique advantages and drawbacks.
- RFA is cheaper for a single treatment, while TOETVA offers superior cosmetic results and patient satisfaction.
- It is crucial to remain vigilant about the possibility of malignancy even in cases with benign cytology before undergoing RFA.

(RLN) injury were consistently recorded. Management details were described as previously<sup>[2]</sup>. Patients without complications were scheduled for discharge on the second postoperative day and received regular follow-up.

### Radiofrequency ablation

RFA was performed under the guidance of a high-resolution linear transducer using RF generators and 18-gauge internally cooled electrodes with active tip lengths of 7/10 mm (RF Medical Co., Ltd., and STARmed Co., Ltd.). Local anaesthesia, a transisthmic approach, and the moving-shot technique were executed as described by Baek<sup>[15]</sup>. Typically, in our institute's protocol, a single session would be dedicated to treating the predominant thyroid nodule causing symptoms. However, if there are other nodules on the same side that also contribute to the symptoms, they will be addressed in the same session.

Contrast-enhanced ultrasonography was not performed because it was not approved for use in Taiwan at the time of this study. After RFA, patients were observed for 30 min to check for any immediate complications in accordance with the definitions by Baek<sup>[16]</sup>. The risk of complications and treatment effectiveness were prospectively assessed both before and after RFA, based on the guidelines of the Korean Society of Thyroid Radiology and the Asian Conference on Tumour Ablation<sup>[17,18]</sup>. A second RFA session was conducted after 1 year if deemed necessary.

### Outcomes

We reviewed medical records for patient characteristics and outcomes, including treatment time, length of hospital stay, and treatment-related morbidity. RFA-related morbidities were documented as described by Mauri<sup>[19]</sup>. Vocal cord movement was assessed using routine ultrasonography (US), and indirect laryngoscopy was performed if symptoms were suspected. Subclinical hypothyroidism was defined as elevated serum thyroid-stimulating hormone levels (TSH, normal range 0.39–4.2 IU/ml) beyond the upper limit, with normal free thyroxine (free T4, normal range 0.89–1.79 ng/dl)<sup>[20]</sup>. Overt hypothyroidism was defined as increased serum TSH and decreased free T4 levels<sup>[21]</sup>.

### Volume reduction ratio

Follow-up was conducted at 3, 6, and 12 months after RFA. The nodule volume was calculated using the following equation: volume = length × width × height × 0.525, and the volume reduction ratio (VRR) was calculated as [(initial volume – final volume) × 100] / initial volume. The size of the TN was characterized by

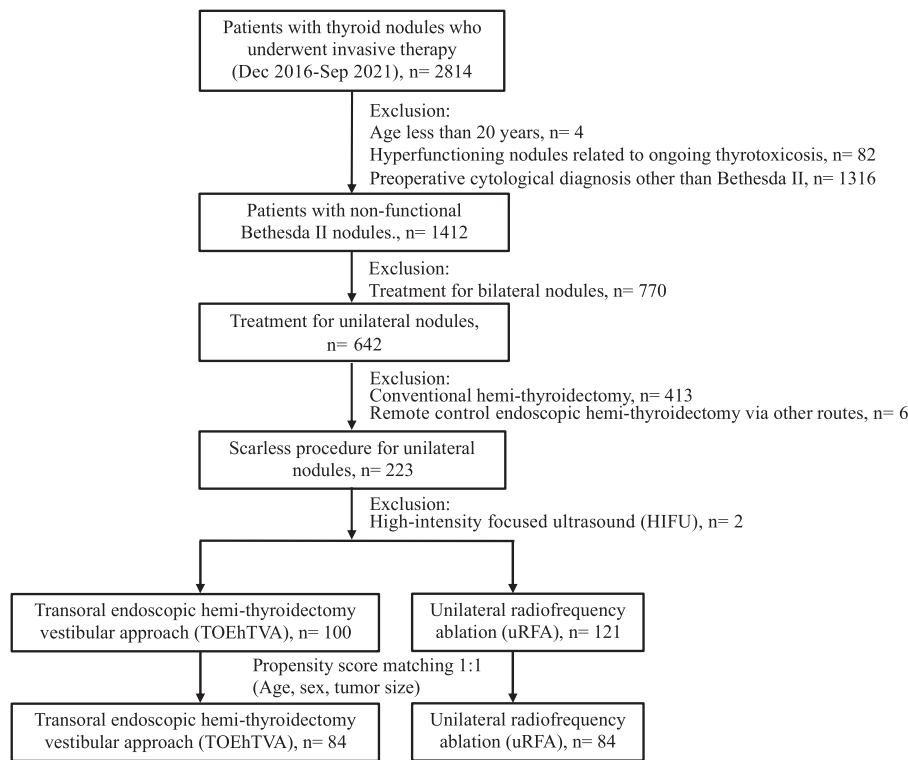


Figure 1. Flow chart for management of 2814 patients with thyroid nodules in this study.

the volume of a single predominant TN. Nodule shrinkage efficacy was evaluated using the VRR at 1 year, with a VRR greater than or equal to 50% at one year considered a parameter for achieving therapeutic success<sup>[22]</sup>.

**Cosmetic improvement**

Cosmetic scores, as graded by clinicians initially and one year after TOETVA or RFA, and patient satisfaction with cosmetic improvement, were regularly recorded 1 year after the procedures. The cosmetic score was assessed by physicians using the

following scale: 1: no palpable mass; 2: no cosmetic problem but a palpable mass; 3: a cosmetic problem on swallowing only; and 4: an easily visible mass<sup>[17]</sup>. To determine satisfaction, patients were asked to rate the improvement in cosmetic outcomes after treatment (no improvement, slight improvement, moderate improvement, and significant improvement)<sup>[23]</sup>.

**Costs**

Costs are expressed in US dollars (USD), converted from Taiwanese dollars (1 USD = 30 TWD). Costs include medical

**Table 1**  
Baseline characteristics between patients with unilateral BTNs who underwent RFA and TOETVA before and after propensity score matching<sup>a</sup>.

Characteristics	Before propensity matching			After propensity matching <sup>a</sup>		
	RFA (n = 121)	TOETVA (n = 100)	P	RFA (n = 84)	TOETVA (n = 84)	P
Patient age, mean (SD), year	50.77 (13.18)	43.20 (14.85)	0.0003***	47.21 (13.17)	45.55 (12.22)	0.4004 <sup>b</sup>
Sex			<0.0001***			0.7867
Male	24 (19.83)	8 (8.00)		8 (9.52)	7 (8.33)	
Female	97 (80.17)	92 (92.00)		76 (90.48)	77 (91.67)	
Longest diameter of predominant nodule, mean (SD), cm	3.83 (1.14)	4.25 (1.22)	0.0106*	3.97 (1.22)	4.14 (1.20)	0.3553 <sup>b</sup>
BMI, mean (SD), kg/m <sup>2</sup>	24.29 (1.60)	22.22 (4.50)	0.7350	23.11 ± 3.78	22.65 ± 3.48	0.4209

Values are presented as mean (SD) or number (percentage, %) of patients unless otherwise indicated. Continuous variables were compared using Student's *t*-test or Welch-Satterthwaite *t*-test and analysis of variance. Categorical variables were compared using the  $\chi^2$  test. BTN, benign thyroid nodules; RFA, radiofrequency ablation; TOETVA, transoral endoscopic thyroidectomy vestibular approach. <sup>a</sup>Propensity score matching was performed with age, sex, and tumour size as covariates. <sup>b</sup>Welch-Satterthwaite *t*-test. Statistical significance, \**P* < 0.05, \*\*\**P* < 0.001.

**Table 2**  
**Comparison of surgical outcomes between patients who underwent RFA and TOETVA after propensity score matching<sup>a</sup>.**

Characteristics	RFA (n=84)	TOETVA (n=84)	P
No. nodule			0.1581
Single	30 (35.71)	39 (46.43)	
Multiple	54 (64.29)	45 (53.57)	
Dimensions of predominant nodule, mean (SD, cm)			
Length	3.88 (1.19)	4.04 (1.23)	0.3841 <sup>b</sup>
Width	3.32 (0.98)	3.30 (1.23)	0.9165 <sup>b</sup>
Height	2.74 (1.27)	2.36 (1.30)	0.5550 <sup>b</sup>
Volume of predominant nodule, mean (SD, cm <sup>3</sup> )	22.75 (20.09)	21.37 (30.09)	0.7262
Component of predominant nodule			> 0.9999 <sup>c</sup>
Solid	81 (96.43)	80 (95.24)	
Predominate solid	3 (3.57)	4 (4.76)	
Distance from the skin and predominant nodule, mean (SD), mm	15.33 (4.43)	15.31 (4.48)	0.9724
Indication for treatment			
Pressure symptoms	48 (57.14)	40 (47.62)	0.2165
Bad cosmesis	75 (89.29)	69 (82.14)	0.1859
Pre-existing hypothyroidism (subclinical)	0 (0.00)	0 (0.00)	NA
Time expenditure, mean (SD), min			
Preparation	17.2 (8.0)	37.8 (11.4)	< 0.0001***
Treatment	30.8 (13.6)	120.7 (36.5)	< 0.0001***
In operation room	53.5 (19.2)	188.8 (53.3)	< 0.0001***
Complications	4 (4.76)	7 (8.33)	0.5348 <sup>c</sup>
Hoarseness	0 (0.00)	0 (0.00)	NA
Haematoma or seroma	1 (1.19)	0 (0.00)	1.000 <sup>c</sup>
Infection	0 (0.00)	1 (1.19)	1.000 <sup>c</sup>
Tumour rupture	3 (3.57)	0 (0.00)	0.2455 <sup>c</sup>
Overt hypothyroidism	0 (0.00)	0 (0.00)	NA
Subclinical hypothyroidism	0 (0.00)	6 (7.14)	1.000 <sup>c</sup>
Hospital stays, mean (SD), day	0.07 (0.46)	1.98 (0.47)	< 0.0001
Costs, mean (SD), USD			
Device and equipment	1641.2 (42.9)	2659.7 (159.8)	< 0.0001
Procedure	407.0 (73.8)	848.8 (28.2)	< 0.0001
Follow-up duration mean (SD, ranges), month	52.6 (17.2, 27.4-94.1)	56.1 (15.9, 27.9-84.8)	0.1744

Values are presented as mean (SD) or number (percentage, %) of patients unless otherwise indicated. Continuous variables were compared using Student's *t*-test or Welch–Satterthwaite *t*-test and analysis of variance.

Categorical variables were compared using the  $\chi^2$  test.

NA, not available; RFA, radiofrequency ablation; TOETVA, transoral endoscopic thyroidectomy vestibular approach; USD, United States Dollar.

<sup>a</sup>Propensity score matching was performed with age, sex, and tumour size as covariates.

<sup>b</sup>Welch–Satterthwaite *t*-test.

<sup>c</sup>Fisher's exact test.

Statistical significance \*\*\**P* < 0.001.

expenses for treatment and hospitalization. Treatment costs encompass procedural, device-related, and other medical expenses. Data on procedures, device, equipment, and other medication costs (analgesics, anaesthesia, and antibiotics) were obtained from Taiwan's National Health Insurance Administration, Ministry of Health and Welfare. Hospitalization costs refer to inpatient care, including readmission for complications.

## Statistical analysis

The data were summarized using descriptive statistics. Categorical variables were presented as numbers and percentages, while continuous variables were expressed as means and standard deviations. Patient characteristics were analyzed using Student's *t*-test or Welch–Satterthwaite *t*-test or analysis of variance for continuous variables and the chi-square test or Fisher's exact test for categorical variables. Propensity score matching was conducted with age, sex, and tumour size as covariates to mitigate confounding bias associated with potential selection effects. This was necessary due to the younger age, higher proportion of women, and larger TNs in the TOETVA group compared to the RFA group.

Statistical analyses were performed using SAS (version 9.4; Cary). All *P* values were two-sided, and significance was defined as *P* less than 0.05.

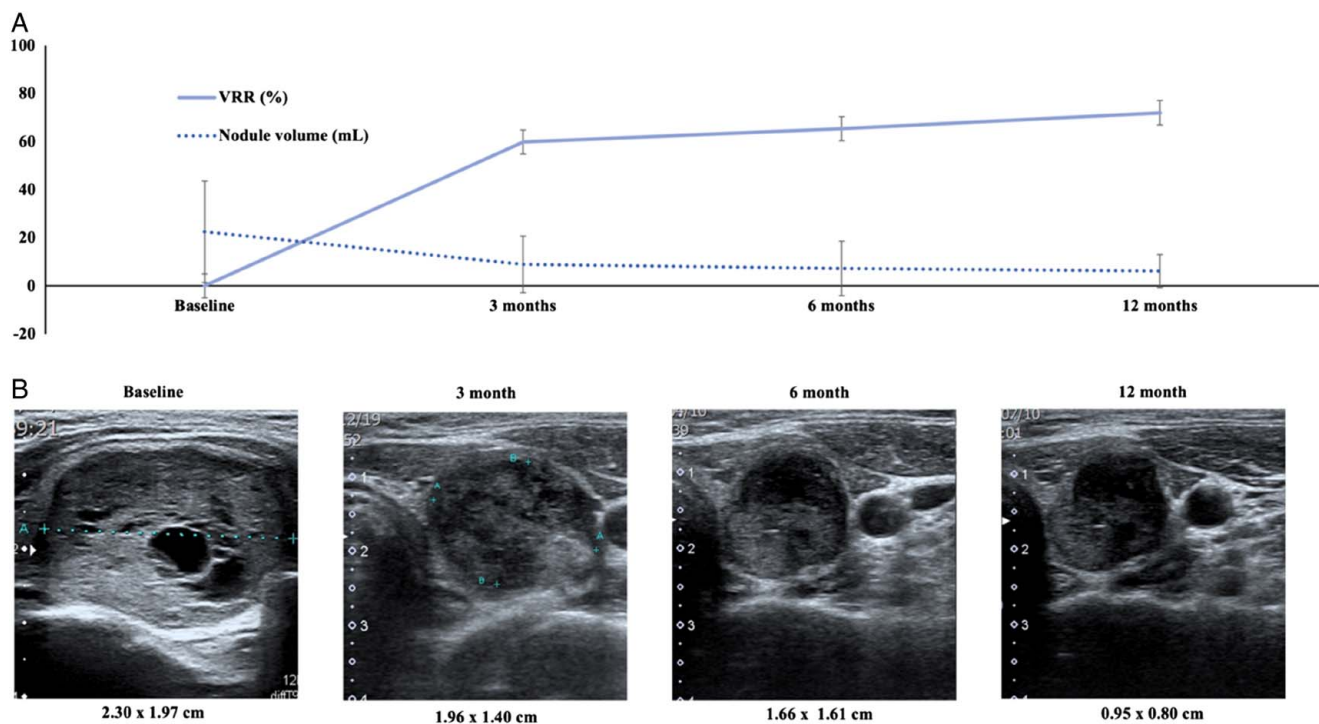
## Results

After Propensity Score Matching, 84 patients were selected for each group (Fig. 1). All baseline characteristics were comparable between the two matched groups (TOETVA vs. RFA, see Table 1 and Table 2), including mean patient age (45.55 vs. 47.21 years, *P* = 0.4004), male sex (7/84 vs. 8/84, *P* = 0.7867), and mean BMI (22.65 vs. 23.11 kg/m<sup>2</sup>, *P* = 0.4209). The mean size of the predominant nodule was comparable in terms of volume (20.35 vs. 21.67 cm<sup>3</sup>, *P* = 0.7262) and also in three dimensions. The indications for treatment were pressure symptoms (47.62% vs. 57.14%, *P* = 0.2165) and poor cosmesis (82.14% vs. 89.29%, *P* = 0.1859). Mean follow-up duration was 56.1 months and 62.6 months on average without a significant difference (*P* = 0.1744).

## Safety and cost of the two procedures

The time spent on the procedure (120.7 ± 36.5 vs. 30.8 ± 13.6 min, *P* < 0.0001), preparation time (37.8 ± 11.4 vs. 17.2 ± 8.0 min, *P* < 0.0001), and time in the operating room (188.8 ± 53.3 vs. 53.5 ± 19.2 min, *P* < 0.0001) were all significantly longer in the TOETVA group than in the RFA group. The hospital stay was also longer in the TOETVA group (1.98 ± 0.47 vs. 0.07 ± 0.46 days, *P* < 0.0001).

There was no statistically significant difference in overall complications between the two groups (8.33% vs. 4.76%, *P* = 0.5348). No patients in either group experienced post-operative hoarseness, and there were no instances of nerve monitoring signal loss during the TOETVA procedures. One patient who underwent RFA developed a haematoma, which improved without further intervention. Three patients who underwent RFA experienced tumour rupture during follow-up, presenting with sudden neck bulging and pain. Their symptoms subsided after two weeks. One patient who underwent TOETVA developed a focal infection, which improved after antibiotic treatment. No patients in either group developed overt hypothyroidism following treatment; however, the incidence of subclinical hypothyroidism at post-treatment 3 months was higher in the TOETVA group than in the RFA group (7.14% vs. 0.00%, *P* = 0.0285) (Table 2). No medication was given to these subclinical hypothyroidism patients, and all of them had a normal TSH level at the checkup at 1 year.



**Figure 2.** (A) Changes in volume reduction ratio (VRR) and nodule volume in 84 enrolled TNs after matching; (B) serial ultrasound images of a solid TN in a 42-year-old female obtained before (baseline), 3 months, 6 months, and 12 months after radiofrequency ablation.

Total costs were higher in the TOETVA group ( $4621.9 \pm 162.3$  vs.  $2059.5 \pm 86.8$  USD,  $P < 0.0001$ ), including device and equipment costs ( $2659.7 \pm 159.8$  vs.  $1641.2 \pm 42.9$  USD,  $P < 0.0001$ ) and procedure costs ( $848.8 \pm 28.2$  vs.  $407.0 \pm 73.8$  USD,  $P < 0.0001$ ) (Table 2).

### Effectiveness of the two procedures

Changes in volume reduction ratio (VRR) and nodule volume after RFA are illustrated in Figure 2. The mean volume of the dominant nodules was  $22.49 \pm 21.04$  cm<sup>3</sup> initially and  $6.27 \pm 6.92$  cm<sup>3</sup> 12 months after RFA. Nodule shrinkage increased over time ( $59.80 \pm 7.17\%$  at 3 months,  $65.34 \pm 27.93\%$  at 6 months, and  $77.72 \pm 57.21\%$  at 12 months). Treatment success, defined as TNs VRR greater than or equal to 50% at 12 months after RFA, was achieved in 76 out of 84 (90.48%) patients. There was no correlation between the size of the prominent nodule and the RFA success rate (see Supplementary Figure 1, Supplemental Digital Content 1, <http://links.lww.com/JS9/B949>). Additionally, 17 patients (20.24%) underwent a second session of ablation 1 year after the first session during follow-up (Table 3).

At baseline, cosmetic scores were comparable between the two groups. However, one year after treatment, the TOETVA group had better scores than the RFA group (score 1 and 2; 100% vs. 54.76%,  $P < 0.0001$ ) (Table 3).

Patient satisfaction with cosmetic improvements is presented in Table 3. More patients in the TOETVA group rated their cosmetic improvement as significant compared to the RFA group (89.29% vs. 61.90%,  $P < 0.0001$ ).

### Pathohistological results

The preoperative cytological diagnosis for both groups of patients was benign nodules. Histopathological diagnosis was only available following TOETVA. The observed cases included 51 adenomatous goitres, 31 follicular adenomas, one follicular variant of papillary thyroid cancer, and one follicular thyroid cancer. Seven cases presented with goitre accompanied by papillary thyroid microcarcinomas (Table 4). No complementary procedures were applied in patients noted to have malignancy in post-TOETVA pathology, and no recurrence or metastasis was observed during the study period.

### Discussion

This study compared the risk of complications, cosmetic outcomes, and costs of RFA and TOETVA in the treatment of unilateral benign TNs. We demonstrated that both procedures have unique complications, but at lower rates. TOETVA achieved superior cosmetic improvements, as evaluated by clinicians and patients, while RFA offers the benefit of being less expensive. This real-world, detailed comparison equips both patients and surgeons to make an optimal choice.

Thyroidectomy is one of the primary therapeutic approaches for treating benign TNs; however, it has several drawbacks<sup>[3]</sup>. The potential for scarring after surgery is a significant consideration for many patients, discouraging them from undergoing conventional transcervical thyroidectomy and driving the demand for scarless procedures<sup>[24]</sup>. RFA, a percutaneous ultrasound-guided procedure that results in a small ablation-related wound, has gained popularity, especially among patients with cosmetic concerns. RFA has demonstrated safety and efficacy,

**Table 3**  
**Effectiveness comparison between patients who underwent RFA and TOETVA after propensity score matching<sup>a</sup>.**

Characteristics	RFA (n=84)	TOETVA (n=84)	P
VRR <sup>b</sup> at 12 months, mean (SD), %	77.72 (57.21)	—	—
VRR <sup>b</sup> ≥ 50% at 12 mo	76 (90.48)	84 (100.00)	0.0070
Received the second RFA	17 (20.24)	—	—
Cosmetic satisfaction at 12 months			
No improvement	3 (3.57)	0 (0.00)	0.2455 <sup>c</sup>
Slight improvement	5 (5.95)	0 (0.00)	0.0588 <sup>c</sup>
Moderate improvement	24 (28.57)	9 (10.71)	0.0036 <sup>**</sup>
Significant improvement	52 (61.90)	75 (89.29)	< 0.0001 <sup>***</sup>
Cosmetic score initially			
1	0 (0.00)	0 (0.00)	NA
2	1 (1.19)	2 (2.38)	1
3	5 (5.95)	12 (14.29)	0.0733
4	78 (92.86)	70 (83.33)	0.0567
Median	4	4	0.0588 <sup>d</sup>
Cosmetic score at 12 months			
1	9 (10.71)	84 (100.00)	< 0.0001
2	37 (44.05)	0 (0.00)	
3	30 (35.71)	0 (0.00)	
4	8 (9.52)	0 (0.00)	
Median	2	1	< 0.0001

Values are presented as mean (SD) or number (percentage, %) of patients unless otherwise indicated. Continuous variables were compared using Student's *t*-test or Welch–Satterthwaite *t*-test and analysis of variance.

Categorical variables were compared using the  $\chi^2$  test.

Cosmetic score was classified on a clinical score: 1: no palpable mass; 2: no cosmetic problem but palpable mass; 3: a cosmetic problem only on swallowing; 4: easily visible mass.

NA, not available; RFA, radiofrequency ablation; TOETVA, transoral endoscopic thyroidectomy vestibular approach; VRR, volume reduction ratio.

<sup>a</sup>Propensity score matching was performed with age, sex, and tumour size as covariates.

<sup>b</sup>VRR was estimated by the equation: VRR (%) = (pre-treated volume – post-treated volume) / pre-treated volume × 100%.

<sup>c</sup>Fisher's exact test.

<sup>d</sup>Mann–Whitney U test.

<sup>e</sup>Welch–Satterthwaite *t*-test.

Statistical significance<sup>\*\*</sup>*P* < 0.01, <sup>\*\*\*</sup>*P* < 0.001.

making it a viable alternative for treating bilateral benign TNs<sup>[25]</sup>. Recent studies have also indicated the effectiveness of the TOETVA with low complication rates<sup>[2]</sup>, establishing it as a scarless procedure due to its shorter access to the thyroid gland compared to other endoscopic thyroidectomy approaches<sup>[26]</sup>.

While new technologies have been proposed, clinicians often grapple with uncertainty regarding their real impact on safety and effectiveness. To the best of our knowledge, this study represents the first attempt to compare these two popular scarless procedures.

Our findings demonstrate that RFA and TOETVA exhibit comparable complication rates. Notably, RFA, as previously reported in the literature, is associated with fewer complications, including neurological injury, hypoparathyroidism, and hypothyroidism when compared with conventional transcervical thyroidectomy<sup>[7]</sup>. Our study specifically focused on TNs necessitating unilateral procedures, which inherently carry a lower risk of complications such as hypoparathyroidism and hypothyroidism compared to bilateral procedures. Traditional thyroidectomy involves the removal of goitres and the surrounding thyroid tissue, while RFA ablates TNs while sparing most of the surrounding normal tissue. Consequently, RFA theoretically better

**Table 4**  
**The histopathology results of TOETVA patients.**

Characteristics	TOETVA	(n=84)
Nodular goitre	51	(60.71)
Follicular/Hurthle cell adenoma	31	(36.90)
FVPTC	1	(1.19)
FTC	1	(1.19)
Accompany PTmC	7	(8.33)

Values are presented as number (percentage, %) of patients unless otherwise indicated.

FTC, Follicular thyroid cancer; FVPTC, Follicular variant of papillary thyroid cancer; PTmC, papillary thyroid microcarcinoma; TOETVA, transoral endoscopic thyroidectomy vestibular approach.

preserves thyroid function. In our study, no cases of hypothyroidism were observed in patients after RFA, consistent with previous studies reporting hypothyroidism in only 0.07% of cases<sup>[27]</sup>. No overt hypothyroidism was observed in patients who underwent TOETVA; however, 7.14% developed subclinical hypothyroidism. The occurrence of hypothyroidism following conventional hemithyroidectomy ranges from 5.0 to 7.8% of cases, depending on the follow-up strategy or the definition of hypothyroidism<sup>[28,29]</sup>, and ~6.7–21.2% of patients require thyroxine supplementation<sup>[30]</sup>. Our study observed a relatively lower hypothyroidism rate, which could be attributed to the inclusion of benign thyroid nodules without extension for oncological concerns. No medication was given to these subclinical hypothyroidism patients after TOETVA, and all of them had a normal TSH level at the checkup at 1 year.

Importantly, no nerve injuries were observed in either group. In the case of RFA, the minimization of RLN injury was achieved through the use of anatomical ultrasound guidance, which allowed for the monitoring of the “danger triangle” where the RLN is situated<sup>[16]</sup>. Our TOETVA procedures routinely incorporated intraoperative neurophysiological monitoring, a quality indicator for RLN function identification, potentially contributing to a lower nerve injury rate than in previous studies<sup>[31]</sup>. Nevertheless, it's worth noting that both treatments come with unique complications. The most common complication after RFA is tumour rupture secondary to acute volume expansion caused by haemorrhage, consistent with previous studies<sup>[16]</sup>. One patient who underwent TOETVA developed a surgical site infection, an occurrence reported in roughly 0.3% of patients in previous studies<sup>[32]</sup>. Notably, none of the patients in our study developed subsequent abscesses, and long-term antibiotic treatment was not required. Further evaluation of possible complications associated with these two procedures may be conducted in subsequent studies.

Lee reported a therapeutic success rate of 78.2% at 6 months after the initial ablation and 93.4% after the final ablation<sup>[22]</sup>. Other studies have reported therapeutic success rates ranging from 85 to 99% after multiple RFA sessions<sup>[33,34]</sup>. Consistent with prior research, our study confirms the potential and efficacy of RFA in the treatment of benign TNs. However, it's worth noting that the common definition of success in previous studies, defined as a greater than 50% VRR for post-thyroid RFA assessment when compared to thyroid surgeries, may introduce bias<sup>[35]</sup>. It is advisable to evaluate success using more objective scales or scores. The assessment of patient satisfaction following thyroid surgery or ablation is challenging. The absence of comprehensive and validated scoring systems has led to the utilization

of various self-administered scales for evaluating patient satisfaction<sup>[36]</sup>. The evaluations conducted in this study were based on cosmetic improvements rated by patients and cosmetic scores rated by clinicians<sup>[35,37]</sup>. Bernardi *et al.*<sup>[35]</sup> demonstrated higher satisfaction regarding symptoms after conventional thyroidectomy, but greater cosmetic satisfaction after RFA (92% vs. 69%,  $P=0.001$ ). Cosmetic dissatisfaction after thyroidectomy is often associated with transcervical incisions. Our findings show that TOETVA outperformed RFA in terms of cosmetic results and patient satisfaction. Importantly, the absence of neck scarring in both procedures allowed for a fair comparison<sup>[37]</sup>. Nonetheless, not all patients who underwent TOETVA were completely satisfied with the cosmetic outcome, suggesting that cosmetic satisfaction was influenced not only by the tumour reduction effect but also by factors such as asymmetry or wrinkles resulting from rapid postoperative tumour volume changes.

Interestingly, histological diagnoses following TOETVA revealed malignancies, including papillary thyroid microcarcinomas accompanied by goitres, follicular thyroid cancer, and follicular variants of papillary thyroid cancer. The predominant TNs in our study had been confirmed as benign through fine-needle aspiration cytology, adhering to the Bethesda 2 categories and in accordance with thyroid RFA guidelines<sup>[18]</sup>. It's noteworthy that Bernardi and colleagues reported that 8% of nodules with benign cytology actually harboured malignancies, and an Italian study reported that 2.4% of these nodules contained microcarcinomas<sup>[33,38]</sup>. Given that a histopathological diagnosis might not be available after ablation, the possibility of malignancy should be taken into consideration. Fortunately, RFA has shown effectiveness in treating low-risk papillary thyroid microcarcinomas, with favourable long-term outcomes and prognosis<sup>[39]</sup>. Additionally, clinicians should be mindful of potential changes observed on ultrasound after RFA, as these changes may falsely suggest malignancy<sup>[40]</sup>. Further research is required to determine whether tumour progression remains unresponsive to thermal treatment during follow-up.

Our findings indicate that TOETVA is more expensive than RFA. The cost of outpatient RFA was demonstrated to be lower than that of short-stay transcervical hemithyroidectomy<sup>[38]</sup>. Until recently, the majority of TOETVA studies have shown that most hospitals still require a postoperative stay of 1–2 days, inevitably resulting in higher hospitalization costs<sup>[2]</sup>. If the future trend for TOETVA includes a model that allows for discharge shortly after surgery, then the cost of hospitalization may significantly decrease. One study found RFA to be more costly than the same-day transcervical hemithyroidectomy due to device and equipment costs<sup>[41]</sup>. In our study, the device-related cost for disposable equipment and modalities in TOETVA was higher than that for RFA. It's important to note that procedural costs may vary among different health insurance payment systems, as seen in other studies, with RFA being approximately two times less expensive<sup>[38]</sup>. However, the cost of RFA may be significantly underestimated since most studies are based on the cost of a single RFA session and do not account for the fact that additional ablations may often be required to achieve optimal results. In our RFA group, 17 patients (20.24%) underwent additional ablation sessions during follow-up. It is reasonable to assume that the 38 patients (45.24%) who still had cosmetic scores of 3 and 4 after one RFA session were likely to require further treatment in the future. When the cost of retreatment is factored in, RFA may not be a cheaper option in terms of the total treatment cost. The true

cost difference between the two procedures should be reevaluated in longer-term studies.

However, our study does have some limitations. First, we did not assess the quality of life or indirect costs. While we focused on unilateral benign TNs, the utility of these techniques for bilateral or cancerous TNs has not been evaluated. Additionally, we did not account for the possibility of regrowth or recurrence after the initial treatment. In conclusion, global multicenter prospective studies with longer follow-up periods are imperative to confirm the long-term safety and cost-effectiveness of these procedures.

## Conclusion

Scarless procedures, including RFA and TOETVA, for the treatment of unilateral benign TNs are effective with few but unique complications. TOETVA achieves higher cosmetic success rates and patient satisfaction. The cost of a single treatment with RFA is lower, but the cost of retreatment must be considered. In addition, clinicians should note that benign cytology before treatment may be accompanied by malignant tumours.

## Ethical approval

Relevant ethics committee: Research Ethics Committee A, National Taiwan University Hospital, No. 7, Chung-Shan South Road, Taipei, Taiwan 100, R.O.C. Reference number: 201906051RINA. State for judgement: approval.

## Consent

All the authors provide assurance that alterations do not distort scientific meaning.

## Source of funding

The work was supported in part by grants from the National Taiwan University Hospital (111-S0125) and the Ministry of Science and Technology (110-2314-B-002-047).

## Author contribution

T.-C.K. and M.-H.W. proposed the study, performed the research, analyzed the data, and wrote the first draft; T.-C.K., K.-Y.C., C.-W.L., and M.-H.W. collected the data; T.-C.K., M.-H.W., Y.-C.W., and M.-T.L. analyzed the data; and C.-H.C. performed the statistical analysis. All authors contributed to the design and interpretation of the study and to the improvement of the manuscript drafts. All the authors have read and agreed to the published version of the manuscript.

## Conflicts of interest disclosure

The authors have no relevant financial disclosures.

## Research registration unique identifying number (UIN)

The study was registered on ClinicalTrials.gov.

Name of the registry: The Analysis of Thyroidectomy and Parathyroidectomy.  
Hyperlink to the registration: <https://clinicaltrials.gov/ct2/show/NCT04569513>.  
Unique identifying number of the study: NCT04569513.

## Guarantor

Ming-Hsun Wu.

## Data availability statement

Due to the sensitive nature of privacy of the patients in this study, all the authors were assured raw data would remain confidential and would not be shared publicly. However, the data base might be available to researchers upon reasonable demands, subject to approval by the responsible ethics committee.

## Provenance and peer review

Not commissioned, externally peer-reviewed.

## Presentation

This work was presented on the 18th Biennial Scientific Meeting of the Asian Association of Endocrine Surgeons (AsAES) in Tokyo Japan on March 16-18, 2023 and the 34th World Congress of International Association of Surgeons, Gastroenterologists, and Oncologists (IASGO) in Verona Italy on September 9-12, 2023.

## Acknowledgements

The authors thank the Department of Medical Research at the National Taiwan University Hospital for technical support during this study.

## References

- [1] Durante C, Costante G, Lucisano G, *et al.* The natural history of benign thyroid nodules. *JAMA* 2015;313:926–35.
- [2] Anuwong A, Ketwong K, Jitpratoom P, *et al.* Safety and outcomes of the transoral endoscopic thyroidectomy vestibular approach. *JAMA Surg* 2018;153:21–7.
- [3] Haugen BR, Alexander EK, Bible KC, *et al.* 2015 American Thyroid Association Management Guidelines for Adult Patients with Thyroid Nodules and Differentiated Thyroid Cancer: The American Thyroid Association Guidelines Task Force on Thyroid Nodules and Differentiated Thyroid Cancer. *Thyroid* 2016;26:1–133.
- [4] Cesareo R, Palermo A, Pasqualini V, *et al.* Efficacy and safety of a single radiofrequency ablation of solid benign non-functioning thyroid nodules. *Arch Endocrinol Metab* 2017;61:173–9.
- [5] Ahn HS, Kim SJ, Park SH, *et al.* Radiofrequency ablation of benign thyroid nodules: evaluation of the treatment efficacy using ultrasonography. *Ultrasonography* 2016;35:244–52.
- [6] Lin WC, Wang CK, Wang WH, *et al.* Multicenter study of benign thyroid nodules with radiofrequency ablation: results of 762 cases over 4 years in Taiwan. *J Pers Med* 2022;12:63.
- [7] Che Y, Jin S, Shi C, *et al.* Treatment of benign thyroid nodules: comparison of surgery with radiofrequency ablation. *AJNR Am J Neuroradiol* 2015;36:1321–5.
- [8] Guan SH, Wang H, Teng DK. Comparison of ultrasound-guided thermal ablation and conventional thyroidectomy for benign thyroid nodules: a systematic review and meta-analysis. *Int J Hyperthermia* 2020;37:442–9.

- [9] Russell JO, Clark J, Noureldine SI, *et al.* Transoral thyroidectomy and parathyroidectomy—A North American series of robotic and endoscopic transoral approaches to the central neck. *Oral Oncol* 2017;71:75–80.
- [10] Kuo TC, Duh QY, Wang YC, *et al.* Practice patterns and learning curve in transoral endoscopic thyroidectomy vestibular approach with neuro-monitoring. *Front Endocrinol (Lausanne)* 2021;12:744359.
- [11] Bauer PS, Murray S, Clark N, *et al.* Unilateral thyroidectomy for the treatment of benign multinodular goiter. *J Surg Res* 2013;184:514–8.
- [12] Moon WJ, Baek JH, Jung SL, *et al.* Ultrasonography and the ultrasound-based management of thyroid nodules: consensus statement and recommendations. *Korean J Radiol* 2011;12:1–14.
- [13] Mathew G, Agha R, Albrecht J, *et al.* STROCCS 2021: Strengthening the reporting of cohort, cross-sectional and case-control studies in surgery. *Int J Surg* 2021;96:106165.
- [14] Randolph GW, Dralle H. International Intraoperative Monitoring Study GAbdullah H, *et al.* Electrophysiologic recurrent laryngeal nerve monitoring during thyroid and parathyroid surgery: international standards guideline statement. *Laryngoscope* 2011;121(Suppl 1):S1–16.
- [15] Jeong WK, Baek JH, Rhim H, *et al.* Radiofrequency ablation of benign thyroid nodules: safety and imaging follow-up in 236 patients. *Eur Radiol* 2008;18:1244–50.
- [16] Baek JH, Lee JH, Sung JY, *et al.* Complications encountered in the treatment of benign thyroid nodules with US-guided radiofrequency ablation: a multicenter study. *Radiology* 2012;262:335–42.
- [17] Kim JH, Baek JH, Lim HK, *et al.* 2017 Thyroid Radiofrequency Ablation Guideline: Korean Society of Thyroid Radiology. *Korean J Radiol* 2018;19:632–55.
- [18] Ha EJ, Baek JH, Che Y, *et al.* Radiofrequency ablation of benign thyroid nodules: recommendations from the Asian Conference on Tumor Ablation Task Force. *Ultrasonography* 2021;40:75–82.
- [19] Mauri G, Pacella CM, Papini E, *et al.* Image-guided thyroid ablation: proposal for standardization of terminology and reporting criteria. *Thyroid* 2019;29:611–8.
- [20] Ross DS. Serum thyroid-stimulating hormone measurement for assessment of thyroid function and disease. *Endocrinol Metab Clin North Am* 2001;30:245–64; vii.
- [21] Sawin CT. Subclinical hypothyroidism in older persons. *Clin Geriatr Med* 1995;11:231–8.
- [22] Lee GM, You JY, Kim HY, *et al.* Successful radiofrequency ablation strategies for benign thyroid nodules. *Endocrine* 2019;64:316–21.
- [23] Lang BHH, Wong CKH, Ma EPM, *et al.* A propensity-matched analysis of clinical outcomes between open thyroid lobectomy and high-intensity focused ultrasound (HIFU) ablation of benign thyroid nodules. *Surgery* 2019;165:85–91.
- [24] Gibelin H, Sierra M, Mothes D, *et al.* Risk factors for recurrent nodular goiter after thyroidectomy for benign disease: case-control study of 244 patients. *World J Surg* 2004;28:1079–82.
- [25] Gharib H, Hegedus L, Pacella CM, *et al.* Clinical review: Nonsurgical, image-guided, minimally invasive therapy for thyroid nodules. *J Clin Endocrinol Metab* 2013;98:3949–57.
- [26] Witzel K, Hellinger A, Kaminski C, *et al.* Endoscopic thyroidectomy: the transoral approach. *Gland Surg* 2016;5:336–41.
- [27] Baek JH, Moon WJ, Kim YS, *et al.* Radiofrequency ablation for the treatment of autonomously functioning thyroid nodules. *World J Surg* 2009;33:1971–7.
- [28] Lang BH, Wong CKH, Wong KP, *et al.* Effect of thyroid remnant volume on the risk of hypothyroidism after hemithyroidectomy: a prospective study. *Ann Surg Oncol* 2017;24:1525–32.
- [29] Verloop H, Louwerens M, Schoones JW, *et al.* Risk of hypothyroidism following hemithyroidectomy: systematic review and meta-analysis of prognostic studies. *J Clin Endocrinol Metab* 2012;97:2243–55.
- [30] Ahn D, Sohn JH, Jeon JH. Hypothyroidism following hemithyroidectomy: incidence, risk factors, and clinical characteristics. *J Clin Endocrinol Metab* 2016;101:1429–36.
- [31] Bai B, Chen W. Protective effects of intraoperative nerve monitoring (IONM) for recurrent laryngeal nerve injury in thyroidectomy: meta-analysis. *Sci Rep* 2018;8:7761.
- [32] Arikian M, Riss P, European TSG. Transoral Thyroidectomy: Initial Results of the European TOETVA Study Group. *World J Surg* 2023;47:1201–8.
- [33] Bernardi S, Giudici F, Cesareo R, *et al.* Five-year results of radiofrequency and laser ablation of benign thyroid nodules: a multicenter study from the Italian Minimally Invasive Treatments of the Thyroid Group. *Thyroid* 2020;30:1759–70.

- [34] Yue WW, Wang SR, Lu F, *et al.* Radiofrequency ablation vs. microwave ablation for patients with benign thyroid nodules: a propensity score matching study. *Endocrine* 2017;55:485–95.
- [35] Bernardi S, Dobrinja C, Carere A, *et al.* Patient satisfaction after thyroid RFA versus surgery for benign thyroid nodules: a telephone survey. *Int J Hyperthermia* 2018;35:150–8.
- [36] Doo AR, Hwang H, Ki MJ, *et al.* Effects of preoperative oral carbohydrate administration on patient well-being and satisfaction in thyroid surgery. *Korean J Anesthesiol* 2018;71:394–400.
- [37] Deandrea M, Sung JY, Limone P, *et al.* Efficacy and safety of radiofrequency ablation versus observation for nonfunctioning benign thyroid nodules: a randomized controlled international collaborative trial. *Thyroid* 2015;25:890–6.
- [38] Bernardi S, Dobrinja C, Fabris B, *et al.* Radiofrequency ablation compared to surgery for the treatment of benign thyroid nodules. *Int J Endocrinol* 2014;2014:934595–10.
- [39] Cho SJ, Baek SM, Lim HK, *et al.* Long-term follow-up results of ultrasound-guided radiofrequency ablation for low-risk papillary thyroid microcarcinoma: more than 5-year follow-up for 84 tumors. *Thyroid* 2020;30:1745–51.
- [40] Wu MH, Chen KY, Chen A, *et al.* Differences in the ultrasonographic appearance of thyroid nodules after radiofrequency ablation. *Clin Endocrinol (Oxf)* 2021;95:489–97.
- [41] Yue WW, Wang SR, Li XL, *et al.* Quality of life and cost-effectiveness of radiofrequency ablation versus open surgery for benign thyroid nodules: a retrospective cohort study. *Sci Rep* 2016;6:37838.