

Thyroid Nodules Treated with Percutaneous Radiofrequency Thermal Ablation: A Comparative Study

A. Faggiano, V. Ramundo, A. P. Assanti, F. Fonderico, P. E. Macchia, C. Misso, F. Marciello, V. Marotta, M. Del Prete, E. Papini, G. Lombardi, A. Colao, and S. Spiezia

Department of Molecular and Clinical Endocrinology and Oncology (A.F., V.R., F.F., P.E.M., F.M., V.M., M.D.P., G.L., A.C.), Federico II University of Naples, 80131 Naples, Italy; Endocrinology (A.F.), National Cancer Institute, Fondazione G. Pascale, 80131 Naples, Italy; Unit of General Surgery, Ultrasound Guided and Neck Pathology Surgery (A.P.A., S.S.), Incurabili Hospital Azienda Sanitaria Locale Napoli 1 Centro, 80131 Naples, Italy; Department of General and Endocrine Surgery (C.M.), Federico II University of Naples, 80131 Naples, Italy; and Department of Endocrinology (E.P.), Regina Apostolorum Hospital, Albano Laziale, 00041 Rome, Italy

Purpose: Percutaneous radiofrequency thermal ablation (RTA) was reported as an effective tool for the management of thyroid nodules (TNs). The aim of this study was to investigate the effects of RTA and to establish whether they were treatment-related by comparison with a matched, untreated control group.

Patients and Methods: The study population included 40 patients with compressive TNs: 22 had nontoxic TNs, and 18 had toxic TNs and were treated with methimazole. In all patients, a fine-needle aspiration cytology was performed to exclude a thyroid malignancy.

Study Design: Twenty patients were treated with RTA (group A), and 20 others did not receive any treatment (group B). At baseline, age, gender, and TN features did not differ significantly between groups. All patients were clinically, biochemically, and morphologically evaluated at baseline and after 1, 3, 6, and 12 months.

Results: TN volume significantly decreased in group A (1.8 ± 0.3 ml at 12 months vs. 13.3 ± 1.8 ml at baseline; $P < 0.0001$) and remained stable in group B [11.7 ± 1.5 ml at 12 months vs. 11.2 ± 1.5 ml at baseline; $P =$ not significant (NS)]. At 3-, 6-, and 12-month evaluations, TN volume was significantly lower in group A than in group B ($P < 0.005$). At the end of the follow-up, pressure symptoms were improved in all patients in group A but persisted unchanged in group B. In group A, hyperthyroidism completely recovered in 40% and improved in 40% of patients with toxic TNs, whereas it persisted in all patients with toxic TNs in group B. RTA was safe and well tolerated in all patients.

Conclusions: RTA induced a marked TN volume shrinkage resulting in parallel improvement of pressure symptoms. In most patients with toxic TNs, hyperthyroidism significantly improved as well. RTA may represent a valid therapeutic approach in patients with TNs not receiving conventional treatments. (*J Clin Endocrinol Metab* 97: 4439–4445, 2012)

Thyroid nodules (TNs) are very common in the general population, with a prevalence of about 50% in subjects older than 60 yr undergoing neck ultrasound examination (1).

The great majority of TNs are benign, but they can be responsible for pressure symptoms in the neck and can result in discomfort and decreased quality of life. Large compressive TNs may result in life-threatening conditions because of the potential acute onset of respiratory crisis. Thyroid surgery and radioiodine therapy are the main therapeutic approaches for compressive TNs (1–3). Surgical complications (both temporary and permanent) are usually reported in 7–10% of cases (4), but the risk of mortality and morbidity for thyroid surgery is sensibly greater in elderly patients due to frequent comorbidity (5, 6). Finally, part of the TN patients fulfilling criteria for surgery refuse this approach. In some of these cases, radioiodine therapy may be ineffective, especially for large non-hyperfunctioning TNs (6–8). Minimally invasive therapeutic options have been proposed to treat TNs when surgery or radioiodine is refused, contraindicated, or ineffective (9).

Percutaneous radiofrequency thermal ablation (RTA) is a minimally invasive procedure that has been developed first to treat patients with liver cancer and has then been used to treat both malignant and benign tumor nodules in many organs (10–14). RTA also represents a promising new approach for the management of TNs (15, 16).

In a previous study, we demonstrated the efficacy and safety of RTA in the treatment of TNs with local pressure symptoms in 39 elderly patients. The benefit-risk ratio appeared elevated, suggesting that this approach may represent a valid alternative in subjects who refuse or who are not candidates for conventional treatments (15). A 2-yr follow-up study showed that RTA is highly effective in achieving long-term shrinkage of large solid TNs as well as in controlling TN-related symptoms in a large series of elderly subjects with compressive TNs (16).

Some other studies further investigated the role of RTA in patients with TNs (15–21), but only one study

evaluated the effectiveness of RTA in a comparative setting (22). In this study, Baek *et al.* (22) performed RTA by using a single-hook 18-gauge needle in 15 patients with benign, nontoxic, predominantly solid TNs. A 6-month follow-up highlighted that the observed TN volume shrinkage was related to RTA activity rather than spontaneous reduction (22).

The current prospective comparative study aims to investigate the long-term effectiveness of RTA in patients with TNs. Both toxic and nontoxic TNs will be evaluated.

Patients and Methods

Study population

Forty consecutive patients (31 women and 9 men; age, 31–86 yr) with solid or predominantly solid (cystic component <30%), large (>4.0 ml) TNs with pressure symptoms that were followed up at the Department of Molecular and Clinical Endocrinology and Oncology, “Federico II” University of Naples, were prospectively enrolled in this study between January 2010 and June 2011. Two patients had unsuccessful surgery, and two other patients had unsuccessful radioactive iodine therapy with ¹³¹I.

Twenty-two patients had nontoxic TNs, and 18 patients had toxic TNs and were treated with antithyroid drugs (methimazole).

Study design

All patients had a complete clinical, hormonal, and B-mode ultrasonography (US) evaluation. To rule out a thyroid malignancy, a US-guided fine-needle aspiration cytology (FNC) was performed on all nodules larger than 1 cm (or less in the presence of US characteristics suspected for malignancy).

As a whole, 44 consecutive subjects with TNs were cytologically evaluated. Four patients were excluded because they had one of the following FNC categories: atypical, follicular neoplasm or suspicious for a follicular neoplasm, suspicious for malignancy, malignant, according to the Bethesda classification (23). Three patients underwent a second FNC evaluation due to nondiagnostic or unsatisfactory cytological specimen. All patients enrolled in the study had benign TNs, negative for malignant cells at the FNC evaluation. Patients enrolled in the study were randomized as follows: 20 patients were treated with a

TABLE 1. Baseline characteristics of patients with TNs

Parameter	Group A	Group B	P
n	20	20	NS
Sex (males/females)	4/16	5/15	NS
Age in years, mean ± SEM (range)	58.3 ± 4.3 (31–86)	62.1 ± 3.1 (36–85)	NS
TN volume (ml)			
Mean ± SEM	13.3 ± 1.8	11.2 ± 1.5	NS
Median	12.35	7.7	
Range	4–27.9	3.6–25.8	
Patients with nontoxic TNs (n)	10	12	NS
Patients with toxic TNs (n)	10	8	NS
SYS score (range)	3.4 ± 0.3 (1–5)	3.0 ± 0.3 (1–5)	NS

Group A, Patients treated with RTA; group B, patients not treated. Statistical analysis was performed by using ANOVA. SYS score, Symptom score expressed as the sum of the single scores including pressure symptoms in the neck, difficulty in swallowing, esthetic complaint.

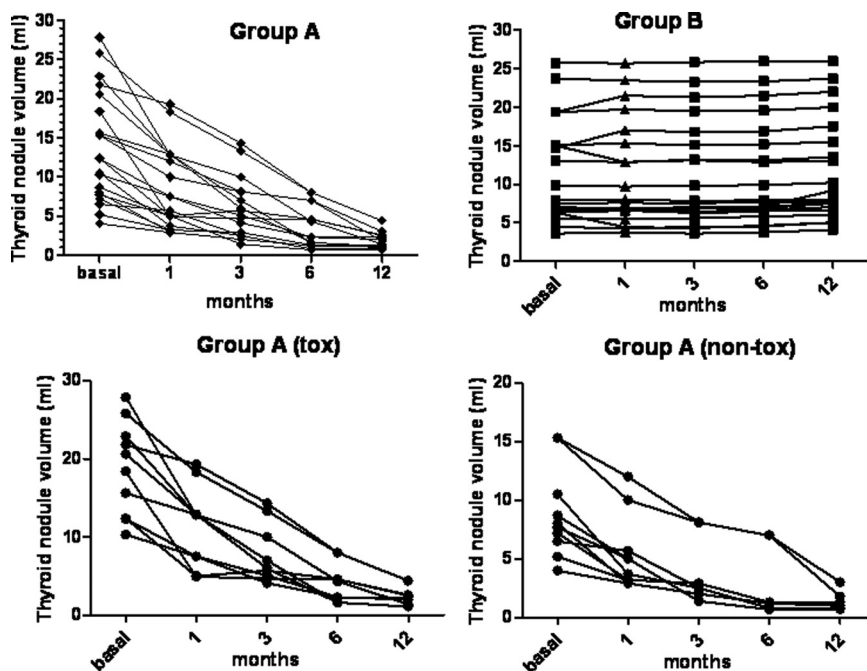


FIG. 1. Top, Profiles of thyroid volume assessed by B-mode US at baseline and at 1-, 3-, 6-, and 12-month follow-up in patients treated with RTA (group A) and untreated patients (group B). Bottom, Profile of thyroid volume assessed by B-mode US at baseline and at 1-, 3-, 6-, and 12-month follow-up in patients treated with RTA (group A) with toxic and nontoxic TNs.

single RTA session (group A), and 20 patients did not receive any treatment and were only followed up (group B). In group A, 10 patients had nontoxic TNs, and 10 patients had toxic TNs. In group B, 12 patients had nontoxic TNs, and eight had toxic TNs.

Inclusion criteria were: age above 18 yr; benign TNs (Thy2); solid or predominantly solid (cystic component < 30%) large (>4.0 ml) TNs; and refusal and/or inefficacy of surgery and/or radioiodine therapy. Exclusion criteria were pregnancy and malignant or suspicious TNs. One nodule per patient was treated with RTA. If a patient had multiple TNs, the largest and most symptomatic one was treated. All patients were clinically, biochemically, and morphologically evaluated at 1, 3, 6, and 12 months after treatment in group A and parallel in group B. Baseline characteristics of patients in group A and group B are shown in Table 1. Age, gender, TN volume, function, and ultrasonographic characteristics did not differ significantly between groups at baseline (Table 1).

The protocol for this study was approved by the Hospital Ethics Committee, and all patients provided written, informed consent before participating in the study (registration no. NCT01649206).

Methods

Clinical evaluation

The TN-related neck symptom score used in the study included pressure symptoms in the neck, difficulty in swallowing, or esthetic complaints, as previously described and validated in a study quantifying the clinical response of patients with TNs to ethanol injection (24). Symptoms were scored separately as follows: 0 (absent), 1 (moderate), and 2 (severe). The sum of the individual scores generated a final score (SYS score) ranging from 0 to 6 (24).

Biochemical evaluation

Serum concentrations of TSH, free T_4 , free T_3 , thyroglobulin, and calcitonin, as well as titers of antithyroglobulin (TgAb) and antithyroperoxidase antibodies (TPOAb) were measured at baseline. TSH, free T_4 , free T_3 , thyroglobulin, TgAb, and TPOAb were also measured at 1-, 3-, 6-, and 12-month follow-up.

US evaluation

US was performed using a 7.5–12 MHz linear probe equipped with CD and PD modules (Technos MPX; Esaote Biomedica, Genova, Italy). Three orthogonal dimensions of TNs were measured on US scans and used to calculate the TN volume through the following ellipsoid equation: length \times width \times depth \times 0.525. A single TN volume was measured in case of uninodular goiter or in case of multinodular goiter when characterized by one predominant nodule associated with other nonclinically significant TNs. In cases of two or more nodules that were confluent in a compressive lobar mass, the volume of the whole mass within the lobe was considered.

Radiofrequency thermal ablation

Percutaneous RTA was carried out using a RITA StarBurst Talon needle (RITA Medical Systems, Fremont, CA) inserted under ultrasonographic guidance. The needle was 14-gauge and 10 cm long and was made up of four hooks expandable to 4 cm. This needle was inserted into each nodule. The hooks were then opened to a maximum of 3.5 cm with an exposure time variable between 5 and 7 min, reaching a maximum temperature variable between 101 and 105 C. After careful cleaning, 2.0–4.0 ml of 2% lidocaine (Xilocaine 2%; AstraZeneca, Basiglio, Italy) was slowly injected into superficial cervical tissue and on the thyroid gland capsule under US guidance. During the RTA procedure, the correct placement of the needle tip, the position of the hooks, and the characteristics and diameters of each RTA-induced lesion were assessed by US. After the procedure, the hooks were retracted, and the needle was slowly pulled out with the radiofrequency energy off. All patients received ice to put on the neck with mild compression and were observed for about 2 h.

Statistical analysis

The statistical analysis was performed by SPSS for Windows version 15.0 (SPSS, Inc., Chicago, IL). Data are reported as mean \pm SEM. The significance was set at 5% ($P < 0.05$). The comparisons between the numerical data were performed by the ANOVA test.

Results

The results of RTA are evaluated by change in TN volume and thyroid function and improvement in clinical symptoms (SYS score).

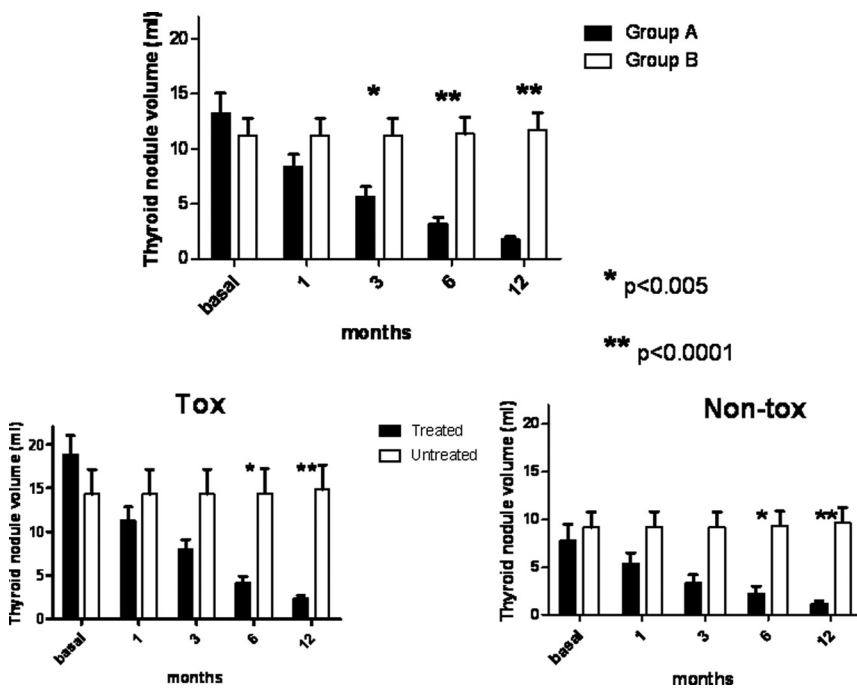


FIG. 2. Top, TN volume (mean \pm SEM) at baseline and 1-, 3-, 6-, and 12-month follow-up in patients treated with RTA (group A) and in untreated patients (group B). Bottom, left, TN volume (mean \pm SEM) at baseline and 1-, 3-, 6-, and 12-month follow-up in patients with toxic TNs treated with RTA vs. untreated patients. Bottom, right, TN volume (mean \pm SEM) at baseline and 1-, 3-, 6-, and 12-month follow-up in patients with nontoxic TNs treated with RTA vs. untreated patients. *, $P < 0.005$; **, $P < 0.0001$, group A vs. group B.

Nodule volume

After treatment, TN volume significantly decreased in group A (8.3 ± 1.2 ml at 1 month, 5.7 ± 0.9 ml at 3 months, 3.2 ± 0.6 ml at 6 months, and 1.8 ± 0.3 ml at 12 months; $P < 0.0001$), whereas it remained unchanged in group B [11.2 ± 1.5 ml at 1 month, 11.3 ± 1.5 ml at 3 months, 11.4 ± 1.5 ml at 6 months, and 11.8 ± 1.5 ml at 12 months; $P =$ not significant (NS)] (Fig. 1). At 3-, 6-, and 12-month evaluations, TN volume was significantly lower in group A than in group B ($P < 0.005$) (Fig. 2). In group A, the mean percentage decrease of TN volume progressively increased during the study period, from $36.5 \pm 2.9\%$ at 1 month to $57.3 \pm 2.5\%$ at 3 months to $76.5 \pm 2.7\%$ at 6 months and 84.9 ± 1.5 at 9 months.

In group A, TN volume decreased significantly in the subgroups of patients with both nontoxic and toxic TNs (Figs. 1 and 2).

Symptoms score and clinical evaluation

SYS score progressively improved in group A from 3.4 ± 0.3 at baseline to 0.6 ± 0.1 at the 12-month evaluation ($P < 0.001$), whereas it worsened in group B from 3.0 ± 0.3 at baseline to 4.1 ± 0.2 at the 12-month evaluation ($P =$ NS) (Fig. 3).

Hormonal evaluation

After treatment, hormonal parameters did not change at any follow-up time. All of the patients in group A who

were euthyroid at baseline had normal serum thyroid function tests after 1, 3, 6, and 12 months, whereas two patients in group B who were euthyroid at baseline experienced a mild decrease of TSH serum levels consistent with a condition of subclinical hyperthyroidism. No significant changes were observed in both groups either in TgAb and TPOAb titers or in calcitonin serum concentrations during the follow-up period.

In the subgroup of patients with toxic TNs in group A, hyperthyroidism completely recovered in four of 10 (40%), as demonstrated by stable euthyroidism after methimazole withdrawal, and improved in four of 10 (40%) as demonstrated by stable euthyroidism after methimazole reduction after RTA. Methimazole therapy was progressively decreased after RTA by halving the initial dose from d 15. In case of stable euthyroidism at the expected time point, then the dose of methimazole was further halved and so on

up to the suspension of the drug. In case of appearance of hormonal signs of hyperthyroidism after dose reduction, the previous dose was restored. On the contrary, hyperthyroidism persisted unchanged in all (100%) patients with toxic TNs in group B that continued therapy with methimazole for the whole 12-month follow-up period.

The mean dose of methimazole was progressively reduced in group A from 6.5 mg/d at baseline to 4.3 mg/d at 1 month, 2.4 mg/d at 3 months, and 2.3 mg/d at 6 and 12 months.

Side effects

In all patients in group A, RTA was safe and well tolerated. No significant side effects were observed, and no patient needed hospitalization after treatment.

Local anesthesia prevented pain on needle insertion and fiber positioning. During the RTA procedure, all patients were asymptomatic, with the exception of a mild sensation of heat in the neck that never required interrupting the procedure. Patients who had undergone RTA were placed under observation for about 2 h after the procedure; no local edema, pain, or other adverse event has been detected.

Discussion

This is the first comparative prospective study evaluating the long-term efficacy and safety of RTA for both toxic

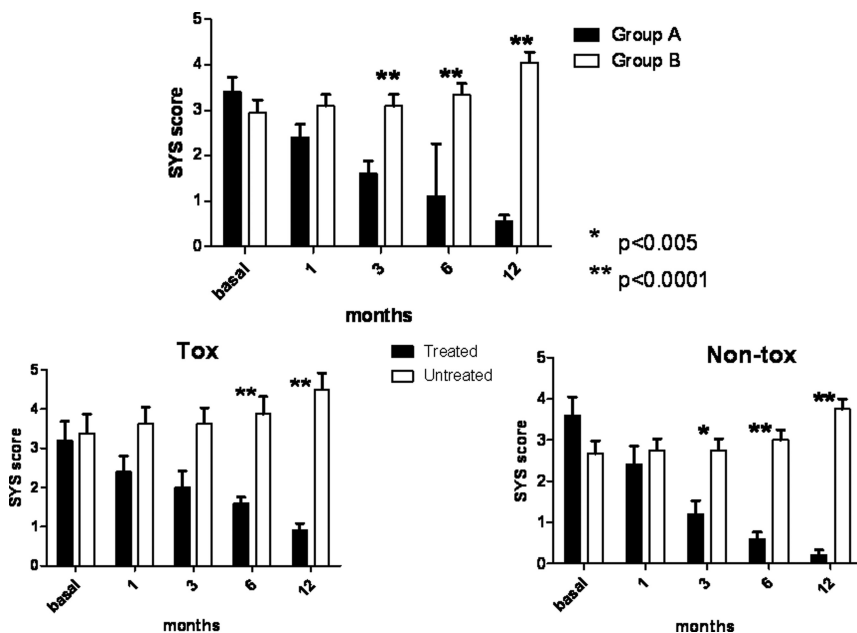


FIG. 3. Top, Symptoms score (mean ± SEM) expressed as the sum of the single scores including pressure symptoms in the neck, difficulty in swallowing, esthetic complaint in patients treated with RTA (group A) and in untreated patients (group B) before and at 1-, 3-, 6-, and 12-month follow-up. Bottom, left, Symptoms score (mean ± SEM) at baseline and at 1-, 3-, 6-, and 12-month follow-up in patients with toxic TNs treated with RTA (group A) vs. untreated patients. Bottom, right, Symptoms score (mean ± SEM) at baseline and at 1-, 3-, 6-, and 12-month follow-up in patients with nontoxic TNs treated with RTA (group A) vs. untreated patients. *, $P < 0.005$; **, $P < 0.0001$, group A vs. group B.

and nontoxic TNs. The main finding of this study was that RTA significantly decreases TN volume in comparison with untreated patients who do not experience any TN size decrease or symptom improvement.

A recent study evaluated the effectiveness of RTA in reducing TN volume by comparing treatment and control groups (22). This study was performed by using a single-hook 18-gauge needle in 15 patients while 15 comparable subjects served as untreated controls. The study population included benign, nontoxic, small TNs, which were predominantly solid but with cystic components up to 40%. A 6-month follow-up highlighted that the observed TN volume shrinkage was related to RTA activity rather than spontaneous reduction (22).

The current study was performed by using a four-hook expandable needle in 20 patients with benign, both toxic and nontoxic, solid or predominantly solid (but with cystic component < 30%), and large (>4.0 ml) TNs and compared them with 20 untreated controls. A long-term 12-month follow-up was performed. This study population and study design well describe the effectiveness of RTA on benign TNs and the potential of this procedure. RTA highly impacts on TN clinical course, inducing a size decrease in all cases and maintaining the results for a long time after treatment. On the other hand, untreated patients had no decrease in TN in any case.

It has to be underlined that cytological evaluation of TNs may result in false-negative diagnoses. This is a limitation for every nonsurgical treatment of TNs, especially for procedures that, by causing tissue damage, limit the usefulness of repeated fine-needle aspiration. That is why a very accurate morphological evaluation of TNs treated with RTA has a central role in the current study, as in similar studies to observe the long-term evolution and the clinical behavior of TNs.

Percutaneous ethanol therapy has been largely used to ablate solid, non-functioning TNs. The procedure is currently abandoned because of both a lack of evidence of long-term efficacy and reports of pain and other serious adverse effects related to seepage of ethanol into perinodular thyroid tissue (1, 9, 25). The present indication for percutaneous ethanol therapy, therefore, is the treatment of thyroid cysts and of predominantly cystic nodules, because of its efficacy and the rare adverse effects (9, 26).

Laser ablation is a thermal technique proposed to treat TNs. Laser ablation induces a 40–60% decrease in the size of TNs over a 6-month period, with stable values during longer-term follow-up. Laser ablation may require more than one session and/or the insertion of multiple optic fibers for treating large TNs. This procedure as well may be associated with an increased risk of local adverse events, especially during the training period (16, 27–29). So far, controlled head-to-head studies comparing the cost-effectiveness of the various mini-invasive procedures are lacking. A recent uncontrolled study comparing RTA to laser ablation concluded that the effectiveness of RTA seems to be slightly superior to laser ablation, and the adverse effects somewhat fewer (30). However, laser ablation has proved to be effective in prospective randomized and in multicenter trials and, when performed in experienced centers, is a rapid, inexpensive, and safe method for inducing a clinically significant nodule debulking.

In patients with symptomatic, benign, multinodular goiter, radioactive iodine can achieve a reduction of about 40% in goiter size within 1 yr (dependent on dose). However, this success comes at the expense of a hypothyroidism rate of about 10–20% (9, 31). For patients with a solitary toxic or pretoxic TN, radioiodine is considered to be first-choice treatment. In the vast majority of patients,

one dose is sufficient to cause a 30–40% size reduction and normalization of thyroid function (9, 25).

Medical therapy with levothyroxine to decrease serum TSH levels in patients with small nonfunctioning TNs achieves very limited, if any, goiter shrinkage and is no longer recommended for routine use in elderly patients and in postmenopausal women because of the adverse effects of subnormal serum TSH levels, especially on bone and the cardiovascular system (9, 32).

The clinical response to RTA is as effective as the ultrasonographic response. TN-related compressive symptoms rapidly improved after RTA, whereas they persisted or worsened in untreated patients. Compressive symptoms were decreased by about 30% at 1 month, by about 50% at 3 months, by about 70% at 6 months, and more than 80% 12 months after treatment with RTA. Percutaneous ethanol injection seems to be highly effective for the treatment of cystic TNs, and compressive and cosmetic symptoms seem to disappear in up to 80% of patients (33). Poor data regarding changes in compressive symptoms after laser therapy are available.

Patients with toxic TNs were also evaluated. In the present study, an improvement of hyperthyroidism and a consequent decrease or withdrawal of methimazole therapy was observed in 80% of cases. Radioiodine therapy has proved to be effective in functioning goiter function (9, 25). In patients with toxic TNs refusing radioiodine therapy, a decrease of nodule volume and normalization of serum TSH levels may be observed after percutaneous ethanol injection (34, 35). Laser thermal ablation also seems to be effective to induce improvement of hyperthyroidism (27).

In the present study, no changes in titers of TgAb and TPOAb or thyroid hormones were observed after RTA in euthyroid patients, thus indicating that this approach is not associated with the development of thyroid autoimmunity or hypothyroidism. On the other hand, hypothyroidism, hypoparathyroidism, and recurrent nerve lesions may follow surgery, which could represent difficult conditions to manage, especially in elderly patients with other comorbidities (6). Radioiodine treatment seems to be associated with increased cardiovascular and cancer mortality, and postradioiodine hypothyroidism occurs in up to 60% after 20 yr (6, 36, 37).

RTA has been recently used for locoregional control of metastatic well-differentiated thyroid carcinoma in patients for whom surgery is not feasible (38). This may represent a new potential use of RTA, further expanding the indications of this innovative approach for thyroid diseases.

In conclusion, RTA is a new therapeutic approach for the management of TNs that is able to control their growth

and to improve both compressive and functioning symptoms. RTA represents a valid approach in patients with TNs who are not candidates, who refuse, or who failed to be cured by conventional treatments. Larger series and longer follow-up are needed to confirm the safety and effectiveness of RTA in the treatment of TNs.

Acknowledgments

Address all correspondence and requests for reprints to: Anton Giulio Faggiano, M.D., Ph.D., Department of Molecular and Clinical Endocrinology and Oncology, “Federico II” University of Naples, Via Sergio Pansini 5, 80131 Naples, Italy. E-mail: afaggiano@unina.it.

This paper was supported by funds from the Department of Molecular and Clinical Endocrinology and Oncology, Federico II University of Naples.

Disclosure Summary: The authors have nothing to disclose.

References

- Gharib H, Papini E 2007 Thyroid nodules: clinical importance, assessment, and treatment. *Endocrinol Metab Clin North Am* 36:707–735, vi
- Mazzaferrri EL 1993 Management of a solitary thyroid nodule. *N Engl J Med* 328:553–559
- Gharib H, Papini E, Paschke R, Duick DS, Valcavi R, Hegedus L, Vitti; PAACE/AME/ETA Task Force on Thyroid Nodules 2010 American Association of Clinical Endocrinologists, Associazione Medici Endocrinologi, and European Thyroid Association medical guidelines for clinical practice for the diagnosis and management of thyroid nodules. *J Endocrinol Invest* 33(5 Suppl):1–50
- Mehta V, Savino JA 1995 Surgical management of the patient with a thyroid disorder. *Clin Geriatr Med* 11:291–309
- Sakorafas GH, Peros G 2006 Thyroid nodule: a potentially malignant lesion; optimal management from a surgical perspective. *Cancer Treat Rev* 32:191–202
- Faggiano A, Del Prete M, Marciello F, Marotta V, Ramundo V, Colao A 2011 Thyroid diseases in elderly. *Minerva Endocrinol* 36: 211–231
- Lippi F, Ferrari C, Manetti L, Rago T, Santini F, Monzani F, Bellitti P, Papini E, Busnardo B, Angelini F, Pinchera A 1996 Treatment of solitary autonomous thyroid nodules by percutaneous ethanol injection: results of an Italian multicenter study. The Multicenter Study Group. *J Clin Endocrinol Metab* 81:3261–3264
- Shetty KR, Duthie Jr EH 1995 Thyroid disease and associated illness in the elderly. *Clin Geriatr Med* 11:311–325
- Hegedüs L 2009 Therapy: a new nonsurgical therapy option for benign thyroid nodules? *Nat Rev Endocrinol* 5:476–478
- Ohtani S, Kochi M, Ito M, Higaki K, Takada S, Matsuura H, Kagawa N, Hata S, Wada N, Inai K, Imoto S, Moriya T 2011 Radiofrequency ablation of early breast cancer followed by delayed surgical resection—a promising alternative to breast-conserving surgery. *Breast* 20:431–436
- Livraghi T, Goldberg SN, Monti F, Bizzini A, Lazzaroni S, Meloni F, Pellicano S, Solbiati L, Gazelle GS 1997 Saline-enhanced radiofrequency tissue ablation in the treatment of liver metastases. *Radiology* 202:205–210
- Lane MD, Le HB, Lee S, Young C, Heran MK, Badii M, Clarkson PW, Munk PL 2011 Combination radiofrequency ablation and ce-

- mentoplasty for palliative treatment of painful neoplastic bone metastasis: experience with 53 treated lesions in 36 patients. *Skeletal Radiol* 40:25–32
13. Teh HS, Tan SM 2010 Radiofrequency ablation—a new approach to percutaneous eradication of benign breast lumps. *Breast J* 16:334–336
 14. Chan MD, Dupuy DE, Mayo-Smith WW, Ng T, DiPetrillo TA 2011 Combined radiofrequency ablation and high-dose rate brachytherapy for early-stage non-small-cell lung cancer. *Brachytherapy* 10:253–259
 15. Spiezia S, Garberoglio R, Di Somma C, Deandrea M, Basso E, Limone PP, Milone F, Ramundo V, Macchia PE, Biondi B, Lombardi G, Colao A, Faggiano A 2007 Efficacy and safety of radiofrequency thermal ablation in the treatment of thyroid nodules with pressure symptoms in elderly patients. *J Am Geriatr Soc* 55:1478–1479
 16. Spiezia S, Garberoglio R, Milone F, Ramundo V, Caiazza C, Assanti AP, Deandrea M, Limone PP, Macchia PE, Lombardi G, Colao A, Faggiano A 2009 Thyroid nodules and related symptoms are stably controlled two years after radiofrequency thermal ablation. *Thyroid* 19:219–225
 17. Baek JH, Moon WJ, Kim YS, Lee JH, Lee D 2009 Radiofrequency ablation for the treatment of autonomously functioning thyroid nodules. *World J Surg* 33:1971–1977
 18. Kim YS, Rhim H, Tae K, Park DW, Kim ST 2006 Radiofrequency ablation of benign cold thyroid nodules: initial clinical experience. *Thyroid* 16:361–367
 19. Deandrea M, Limone P, Basso E, Mormile A, Ragazzoni F, Gamarra E, Spiezia S, Faggiano A, Colao A, Molinari F, Garberoglio R 2008 US-guided percutaneous radiofrequency thermal ablation for the treatment of solid benign hyperfunctioning or compressive thyroid nodules. *Ultrasound Med Biol* 34:784–791
 20. Jeong WK, Baek JH, Rhim H, Kim YS, Kwak MS, Jeong HJ, Lee D 2008 Radiofrequency ablation of benign thyroid nodules: safety and imaging follow-up in 236 patients. *Eur Radiol* 18:1244–1250
 21. Baek JH, Jeong HJ, Kim YS, Kwak MS, Lee D 2008 Radiofrequency ablation for an autonomously functioning thyroid nodule. *Thyroid* 18:675–676
 22. Baek JH, Kim YS, Lee D, Huh JY, Lee JH 2010 Benign predominantly solid thyroid nodules: prospective study of efficacy of sonographically guided radiofrequency ablation versus control condition. *AJR Am J Roentgenol* 194:1137–1142
 23. Cibas ES, Ali SZ 2009 The Bethesda system for reporting thyroid cytopathology. *Am J Clin Pathol* 132:658–665
 24. Zingrillo M, Collura D, Ghiggi MR, Nirchio V, Trischitta V 1998 Treatment of large cold benign thyroid nodules not eligible for surgery with percutaneous ethanol injection. *J Clin Endocrinol Metab* 83:3905–3907
 25. Hegedüs L 2004 Clinical practice. The thyroid nodule. *N Engl J Med* 351:1764–1771
 26. Bennedbaek FN, Hegedüs L 2003 Treatment of recurrent thyroid cysts with ethanol: a randomized double-blind controlled trial. *J Clin Endocrinol Metab* 88:5773–5777
 27. Spiezia S, Vitale G, Di Somma C, Pio Assanti A, Ciccarelli A, Lombardi G, Colao A 2003 Ultrasound-guided laser thermal ablation in the treatment of autonomous hyperfunctioning thyroid nodules and compressive nontoxic nodular goiter. *Thyroid* 13:941–947
 28. Papini E, Guglielmi R, Bizzarri G, Pacella CM 2004 Ultrasound-guided laser thermal ablation for treatment of benign thyroid nodules. *Endocr Pract* 10:276–283
 29. Døssing H, Bennedbaek FN, Hegedüs L 2006 Effect of ultrasound-guided interstitial laser photocoagulation on benign solitary solid cold thyroid nodules: one versus three treatments. *Thyroid* 16:763–768
 30. Baek JH, Lee JH, Valcavi R, Pacella CM, Rhim H, Na DG 2011 Thermal ablation for benign thyroid nodules: radiofrequency and laser. *Korean J Radiol* 12:525–540
 31. Hegedüs L, Bonnema SJ, Bennedbaek FN 2003 Management of simple nodular goiter: current status and future perspectives. *Endocr Rev* 24:102–132
 32. Gharib H, Papini E, Valcavi R, Baskin HJ, Crescenzi A, Dottorini ME, Duick DS, Guglielmi R, Hamilton Jr CR, Zeiger MA, Zini M; AACE/AME Task Force on Thyroid Nodules 2006 American Association of Clinical Endocrinologists and Associazione Medici Endocrinologi medical guidelines for clinical practice for the diagnosis and management of thyroid nodules. *Endocr Pract* 12:63–102
 33. Valcavi R, Frasoldati A 2004 Ultrasound-guided percutaneous ethanol injection therapy in thyroid cystic nodules. *Endocr Pract* 10:269–275
 34. Guglielmi R, Pacella CM, Bianchini A, Bizzarri G, Rinaldi R, Graziano FM, Petrucci L, Toscano V, Palma E, Poggi M, Papini E 2004 Percutaneous ethanol injection treatment in benign thyroid lesions: role and efficacy. *Thyroid* 14:125–131
 35. Tarantino L, Francica G, Sordelli I, Sperlongano P, Parmeggiani D, Ripa C, Parmeggiani U 2008 Percutaneous ethanol injection of hyperfunctioning thyroid nodules: long-term follow-up in 125 patients. *AJR Am J Roentgenol* 190:800–808
 36. Ceccarelli C, Bencivelli W, Vitti P, Grasso L, Pinchera A 2005 Outcome of radioiodine-131 therapy in hyperfunctioning thyroid nodules: a 20 years' retrospective study. *Clin Endocrinol (Oxf)* 62:331–335
 37. Metso S, Jaatinen P, Huhtala H, Auvinen A, Oksala H, Salmi J 2007 Increased cardiovascular and cancer mortality after radioiodine treatment for hyperthyroidism. *J Clin Endocrinol Metab* 92:2190–2196
 38. Baek JH, Kim YS, Sung JY, Choi H, Lee JH 2011 Locoregional control of metastatic well-differentiated thyroid cancer by ultrasound-guided radiofrequency ablation. *AJR Am J Roentgenol* 197:W331–W336